


AAO 2014 Chicago

Instruction Course Number: 514


Course Title: Argon Laser Peripheral Iridoplasty – All You Need to Know
 Date and Time: Tuesday, October 21, 2014. 9:00 AM to 10:00 AM.
 Location: Room S105BC
 Target Audience: Comprehensive & Subspecialist
 Education Level: Intermediate

Instructor



Clement C. Y. Tham, BM BCh(Oxon), FRCS(Glasgow)
 S.H. Ho Professor of Ophthalmology and Visual Sciences, The Chinese University of Hong Kong
 Honorary Chief-of-Service, Hong Kong Eye Hospital
 Director, CUHK Eye Centre
 Deputy Director, Joint Shantou International Eye Centre
 Secretary General, Asia-Pacific Academy of Ophthalmology (APAO)
 Tel: (852) 3943 5823
 Fax: (852) 2816 7093
 E-mail: clemtham@cuhk.edu.hk
 Website: www.ovs.cuhk.edu.hk
 Biography: <http://www.cuhk.edu.hk/medint/ovs/dovs/clementtham.html>

Instructor



Robert Ritch, MD, FACS, FRCOphth
 Shelley and Steven Einhorn Distinguished Chair
 Professor of Ophthalmology
 Chief, Glaucoma Service
 Surgeon Director
 New York Eye and Ear Infirmary, New York, NY, USA
 Tel: 212-673-5140
 Fax: 212-420-8743
 Email: ritchmd@earthlink.net
 Website: www.glaucoma.net

Contents of Instruction Course Handout

Synopsis and Objective of Instruction Course	P.3
Rundown of Instruction Course	P.4
Introduction	P.5
Indications for ALPI and outcomes	P.6-10
Primary angle closure glaucoma – acute and chronic	P.6
Secondary angle closure glaucomas	P.8
Nanophthalmos	P.9
Other uses	P.10
Contraindications	P.11
Techniques of ALPI	P.12-14
Pretreatment measures	P.12
Laser parameters	P.12
Postoperative treatments	P.14
Complications of ALPI and management	P.15
Conclusions	P.16
References	P.17-20

Synopsis and Objective of Instruction Course

Synopsis

This course covers all you need to know about Argon Laser Peripheral Iridoplasty (ALPI), from indications, contraindications, techniques and pearls, results, to complications and their management. Slit lamp photographs and videos are extensively used in the course, the handout, and the course DVD-ROM to illustrate the critical techniques.

Objective

At the conclusion of this course, the attendee will be able to safely, effectively, and confidently, perform ALPI in the appropriate patients.

Rundown of Instruction Course

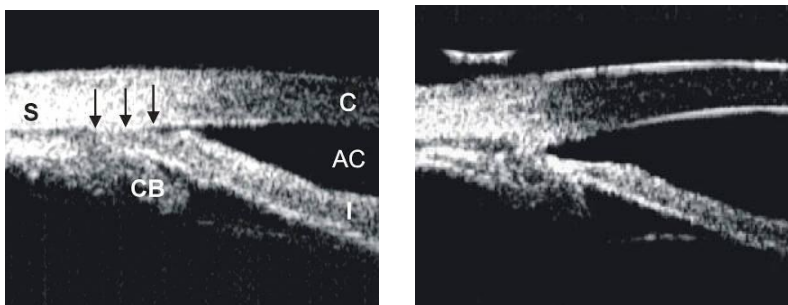
Topic	Time	Speaker
Welcome & overview	2 min.	Clement CY Tham
Introduction What is ALPI? History and developments	5 min.	Clement Tham
Indications for ALPI and outcomes Acute and chronic angle closure Plateau iris syndrome Continued apposition after LPI Phacomorphic and malignant glaucoma Nanophthalmos Contraindications	15 min	Robert Ritch
Techniques of ALPI Pretreatment measures Laser parameters Postoperative treatments Retreatment Surgical tips & Pearls	15 min.	Clement Tham
Special situations Retreatment New developments and other uses Complications and management	10 min.	Robert Ritch
Concluding Remarks	3 min.	Clement CY Tham
Q & A	10 min.	

Introduction

What is Argon Laser Peripheral Iridoplasty (ALPI)?

Argon laser peripheral iridoplasty (ALPI) is a simple and effective means of opening an appositionally closed angle in situations in which laser iridotomy either cannot be performed or does not eliminate appositional closure because mechanisms other than pupillary block are present. It consists of placing contraction burns (long duration, low power, and large spot size) in the iris periphery to contract the stroma at the site of the burn, physically pulling open the angle (Figure 1).¹⁻⁵ ALPI is useful in reversing an attack of acute angle-closure (AAC), either as an initial measure or when antiglaucoma medications fail. The diagnostic indications for ALPI require the ability to differentiate subtle gonioscopic findings. The examiner must be facile with darkroom indentation gonioscopy and with the anatomic causes of angle-closure and the means of diagnosing these clinically.⁶

Figure 1. Ultrasound biomicroscopic (UBM) images illustrating how ALPI contracts the peripheral iris stroma, creating a space between the anterior iris surface and the trabecular meshwork, thus opening the angle. Left: appositionally closed angle in an eye with plateau iris syndrome. Right: open angle after ALPI.



History and developments

Krasnov⁷ was the first to attempt to use laser burns near the iris root to separate iris and trabecular meshwork. The initial procedure encompassed only 90° of the angle. The laser parameters used in these early attempts were more like penetrating burns than the slow contraction burns which later proved optimal, and were often unsuccessful because of insufficient retraction of the iris from the meshwork. Kimbrough et al⁸ described a technique for direct treatment of 360° of the peripheral iris through a gonioscopy lens, and termed the procedure *gonioplasty*.

Table 1 summarizes the indications and contraindications for ALPI.

Indications for ALPI	Contraindications for ALPI
<p>Acute angle closure</p> <p>Chronic angle closure</p> <p>Plateau iris syndrome</p> <p>Angle closure due to size or position of lens</p> <p>Malignant glaucoma</p> <p>Nanophthalmos</p>	<p>Severe and extensive corneal edema or opacity</p> <p>Flat anterior chamber</p> <p>Synechial angle closure</p>

Indications for ALPI and outcomes

Primary angle closure glaucoma – acute and chronic

Acute Angle-Closure

Laser peripheral iridotomy (LPI) is the definitive treatment for acute angle-closure in order to eliminate any component of pupillary block, even if other mechanisms are present or predominate. An attack of AAC that is unresponsive to medical therapy and in which corneal edema, a shallow anterior chamber, or marked inflammation precludes immediate iridotomy, or an attack which is unresponsive despite successful iris penetration by iridotomy, may be broken with ALPI.^{1, 9-12} Circumferential treatment of the iris opens the angle in those areas in which there are no peripheral anterior synechiae (PAS). Since ALPI does not eliminate pupillary block, LPI is still required once IOP is controlled and the cornea has cleared sufficiently.

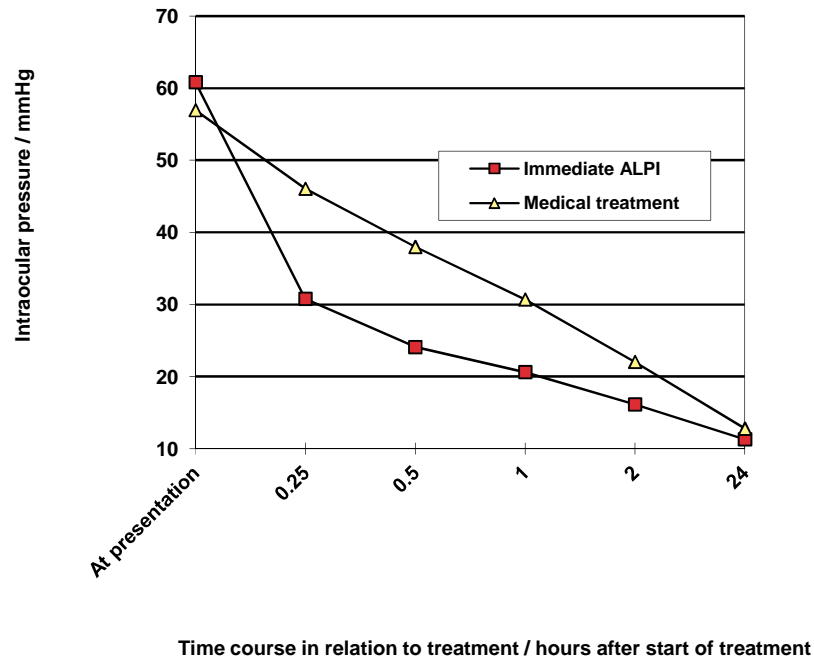
All published series have reported virtually 100% success. In a prospective study of 10 eyes with medically unbreakable attacks lasting 2-5 days, mean prelaser IOP was 54.9 mmHg and 2-4 hours postlaser was 18.9 mmHg.¹² Even when extensive PAS are present, the IOP is usually normalized within an hour or two. The effect lasts sufficiently long for the cornea and anterior chamber to clear so that iridotomy can be performed.

ALPI may also be used as initial therapy in eyes with AAC, either with or without preliminary medical treatment.^{1, 12-18} Immediate ALPI for acute attacks after initial treatment with 4% pilocarpine and 0.5% timolol has been reported successful when given over both 180 degrees¹⁶ and 360 degrees of the peripheral iris.¹⁴

This implies that any opacification obstructing laser access to part of the peripheral iris, e.g. by pterygium, still provides enough access for successful performance of ALPI. Immediate diode laser peripheral iridoplasty in conjunction with topical medications is also successful.¹⁹ The diode laser may be more effective at tissue penetration in the presence of a hazy cornea.²⁰

ALPI is a safe and effective alternative to antiglaucoma medications for initial treatment of AAC.^{15, 21} A randomized trial comparing ALPI and medications was performed in consecutive patients presenting with AAC and IOP >40 mmHg, who were not amenable to immediate LPI.¹⁵ After receiving 4% pilocarpine and 0.5% timolol in the AAC eye, the patients were randomized to immediate ALPI (33 eyes of 32 patients) or intravenous acetazolamide followed by oral acetazolamide (40 eyes of 32 patients), until IOP normalized. The latter group also received intravenous mannitol if the presenting IOP was >60 mmHg. The mean IOP in the ALPI-treated group was reduced from 60.8 ± 11.6 mmHg at presentation to 20.6 ± 10.1 mmHg one hour after ALPI. The ALPI-treated group had significantly lower IOP than the medically treated group at 15 minutes, 30 minutes, and 1 hour after initiation of treatment (Figure 2). The duration of the attack did not affect the efficacy of ALPI in reducing IOP. Longer follow up (mean 15.7 months) of these patients revealed no significant differences between the two groups in mean IOP, requirement for antiglaucoma medications, or the extent of PAS.²² It should be stressed that since ALPI does not eliminate pupillary block, a laser peripheral iridotomy is still required in AAC eyes once IOP is controlled and the cornea has cleared sufficiently.

Figure 2. Randomized controlled trial comparing ALPI against conventional systemic IOP-lowering medications as first-line treatment of AAC - Profiles of mean IOP before and at various time points after commencement of treatment in the two treatment groups.¹⁵



Chronic Angle-closure

Eyes with chronic angle-closure (CAC) and a combination of PAS and appositional closure can respond to ALPI with opening of the appositionally closed portions of the angle. Of 11 eyes with IOP >20 mmHg despite maximal medical therapy, all responded with initial lowering of IOP initially and 7 remained controlled at 6 months, while 4 required trabeculectomy.²³ In a study comparing the long-term clinical course in eyes with optic nerve head and visual field damage in patients in New York and Singapore, 31.3% of the New York eyes went on to filtering surgery compared to 53.0% of the Singapore eyes.²⁴ Seven eyes in the New York group underwent ALPI, after which IOPs were controlled and surgery was not required, while ALPI was not performed in the Singapore patients.

If extensive PAS are present after ALPI, goniosynechialysis (GSL) may be performed, surgically stripping PAS from the angle wall to restore aqueous access to the trabecular meshwork. GSL is thought to be useful only if the PAS have been present for less than one year.²⁵ Promising results have been reported in both phakic and pseudophakic eyes.^{19, 26-30} It is effective both alone and in conjunction with other surgical procedures, such as cataract extraction.^{19, 26, 27, 31} In eyes having had AAC with PAS, combined cataract extraction and GSL was more effective than GSL alone.³² It is also effective when only the inferior 180 degrees of PAS is re-opened.^{19, 27} In one study, 13 patients with IOP >21 mmHg (30.2 ± 8.1) without medications and PAS >180° (301.8 ± 66.5) after phacoemulsification with posterior chamber intraocular lens implantation underwent GSL. At the final follow-up (27.1 ± 17.8 months) after GSL, IOP was <21 mmHg in 10 eyes (13.6 ± 2.3 mmHg) without and in 3 with medications. The mean extent of PAS in the patients with controlled IOP without medications was reduced to 78.6 ± 14.6 degrees. It was concluded that GSL further improves the success by eliminating the need for antiglaucoma

medications and that performing the two procedures simultaneously should be more advantageous than performing them separately Teekhasaenee C, Ritch R: Combined phacoemulsification and goniosynechialysis for uncontrolled chronic angle-closure glaucoma after acute angle-closure glaucoma, *Ophthalmology* 1999;106:669-675. (Teekhasaenee C, Ritch R: Goniosynechialysis for chronic angle-closure with uncontrolled intraocular pressure following phacoemulsification and intraocular lens (IOL) implantation, presented at the 4th International Congress of Glaucoma Surgery, Toronto, June 1, 2006). Peripheral iridoplasty can be performed postoperatively to further flatten the peripheral iris and prevent synechial reattachment.^{19, 26, 27, 30}

Secondary angle closure glaucomas

Plateau iris syndrome

A large or anteriorly positioned ciliary body can maintain the iris root in proximity to the trabecular meshwork, creating a configuration known as plateau iris.³³⁻³⁶ On gonioscopy, the iris root angulates forward and then centrally. In plateau iris syndrome,³⁷ the angle remains appositionally closed or occludable following LPI. Before iridotomy, the anterior chamber is usually of medium depth and the iris surface mildly convex. If pupillary block is either not a component mechanism of the angle-closure or has been eliminated by iridotomy, physical blockage of the angle can be eliminated by ALPI, which compresses the iris root and creates a space where none was before (Figure 3).

ALPI is successful long-term in eyes with plateau iris syndrome.³⁸ Of 23 eyes with a mean follow-up of 79 months, the angle in 20 eyes (87.0%) remained open throughout follow-up after only one treatment.³⁸ In 3 eyes, there was gradual re-closure of the angle years later, but they were readily re-opened and maintained open by a single repeat treatment. No filtration surgery was necessary in these patients during follow-up.

A combined laser technique, with ALPI and sequential LPI in one sitting, has been proposed as initial treatment for eyes with plateau iris syndrome.³⁹ ALPI has also been shown to be effective in opening up appositionally closed segments of the drainage angle in plateau-like iris configuration resulting from iridociliary cysts.⁴⁰

When ALPI is used to open appositionally closed segments of the angle in the presence of a patent iridotomy, a shorter duration of angle closure prior to treatment may be associated with a higher success rate.⁴¹

Figure 3A. UBM image of an eye with plateau iris syndrome after laser peripheral iridotomy.

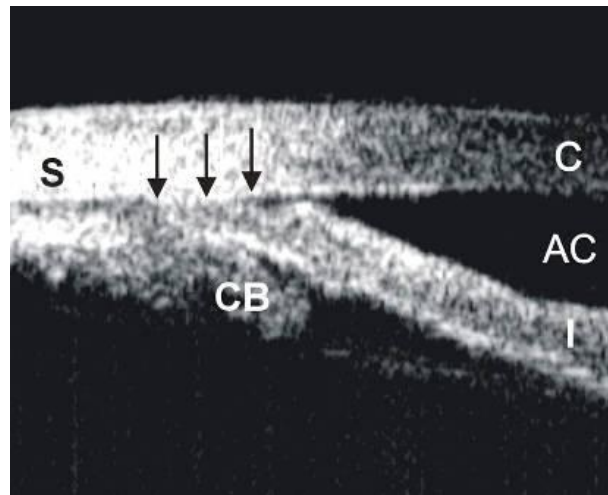
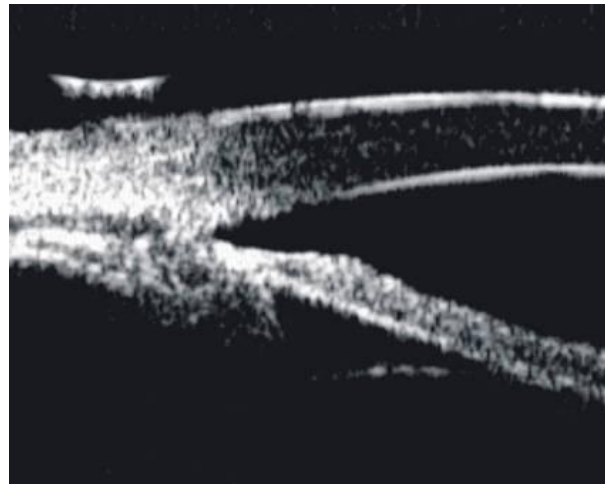


Figure 3B. UBM image of the same eye after ALPI to open the drainage angle.



Lens-related angle closure glaucoma (phacomorphic glaucoma)

Angle-closure caused by an enlarged lens or pressure posterior to the lens (malignant glaucoma, aqueous misdirection, ciliary block) is not often responsive to iridotomy, although a component of pupillary block may be present and should be eliminated by iridotomy. These include such types of angle-closure as ciliary block, lens intumescence, anterior lens subluxation, or anterior lens displacement secondary to ciliary body edema from panretinal photocoagulation, scleral buckling procedures, or acquired immunodeficiency syndrome. In these situations in which the angle remains appositionally closed after LPI, the apposition can often be partially or entirely eliminated by iridoplasty.^{3, 4, 42, 43} After the angle has been opened and IOP reduced, cycloplegics may be given cautiously to ascertain the mechanism of the angle-closure. Further definitive surgical intervention may be necessary after ALPI. However, in secondary malignant glaucoma, the underlying cause of the condition, such as supraciliary effusion after panretinal photocoagulation, resolves after a few weeks and observation usually suffices after ALPI and LPI have been performed.

ALPI is also effective as initial treatment to break attacks of acute phacomorphic angle-closure.^{1, 44, 45, 46} In a prospective case series, 10 consecutive patients with acute phacomorphic angle-closure received topical atropine (1%), timolol (0.5%), and immediate ALPI as initial treatment.⁴⁴ After ALPI, the mean IOP was reduced

from 56.1 ± 12.5 mmHg to 37.6 ± 7.5 mmHg at 30 minutes, 25.5 ± 8.7 mmHg at 120 minutes, and 13.6 ± 4.2 mmHg at one day. All 10 patients had uncomplicated cataract extraction soon after ALPI. No complications from the laser procedure were encountered.

In a more recent randomized controlled trial, 10 consecutive patients with acute phacomorphic angle-closure were randomized to receive either ALPI or systemic carbonic anhydrase inhibitor as initial treatment.⁴⁶ In this study, the ALPI-treated group took significantly less time to achieve an IOP of less than 25 mmHg (18.8 ± 7.5 minutes versus 115.0 ± 97.0 minutes, $P = 0.001$, F test), and had a significantly greater IOP reduction within 30 minutes ($69.8\% \pm 7.7\%$ versus $40.9\% \pm 23.9\%$, $p = 0.03$, t-test). The authors concluded that ALPI may offer greater safety, consistency, and efficacy than systemic IOP-lowering medications as initial treatment for acute phacomorphic angle closure.

In acute phacomorphic angle-closure, the eye is very often severely inflamed, as these patients have usually been referred after being treated unsuccessfully for a few days. Breaking the attack with ALPI may allow a week or more for the inflammation and folds in Descemet's to clear, permitting cataract extraction under conditions much closer to ideal. Any element of pupillary block is treated with LPI as soon as possible (usually within two to three days) after breaking the attack.

Nanophthalmos

These patients are anatomically predisposed to angle-closure due to anterior chamber crowding. Choroidal effusions and ciliary block may occur following intraocular surgical procedures. If appositional closure persists after LPI, ALPI is indicated. Prophylactic iridotomy is not without risk. Bilateral nonrhegmatogenous retinal detachments have been described following LPI in these patients⁴⁸ and may be attributable to worsening of preexisting retinal or choroidal disease.⁴⁹

Other uses

ALPI has been reported useful in dealing with various clinical situations, including improving visual function following multifocal intraocular lens implantation,⁵⁰ treatment of optic obstruction in eyes with the Boston keratoprosthesis,⁵¹ as an adjunct to goniosynechialysis, and in angle closure associated with a cobblestone iris configuration.⁵²⁻⁵⁷

Contraindications

Severe and extensive corneal edema or opacification

In AAC, moderate degrees of corneal edema are not a contraindication to ALPI. If necessary, glycerine may help clear the cornea temporarily to facilitate performing the procedure. When ALPI is used as the initial treatment in AAC, treatment to only 180° of the peripheral iris may be sufficient to abort the attack, and so obstruction to optical access to part of the peripheral iris, e.g. by pterygium, need not be a contraindication to ALPI.¹⁶

Flat anterior chamber

Corneal endothelial burns are generated by heating of the aqueous humor at the site of the laser burn and its reflux toward the corneal endothelium. If the iris is apposed to the cornea, any attempt at photocoagulation will result in damage to the corneal endothelium. If the anterior chamber is very shallow, laser applications should be timed enough apart so that heat generated can dissipate.

Synechial angle closure

ALPI is successful in relieving appositional closure, but not that due to PAS in eyes with uveitis, neovascular glaucoma, or the iridocorneal-endothelial (ICE) syndrome. Although ALPI has been reported to break PAS,⁵⁸ we have been unable to accomplish this.

Techniques of ALPI

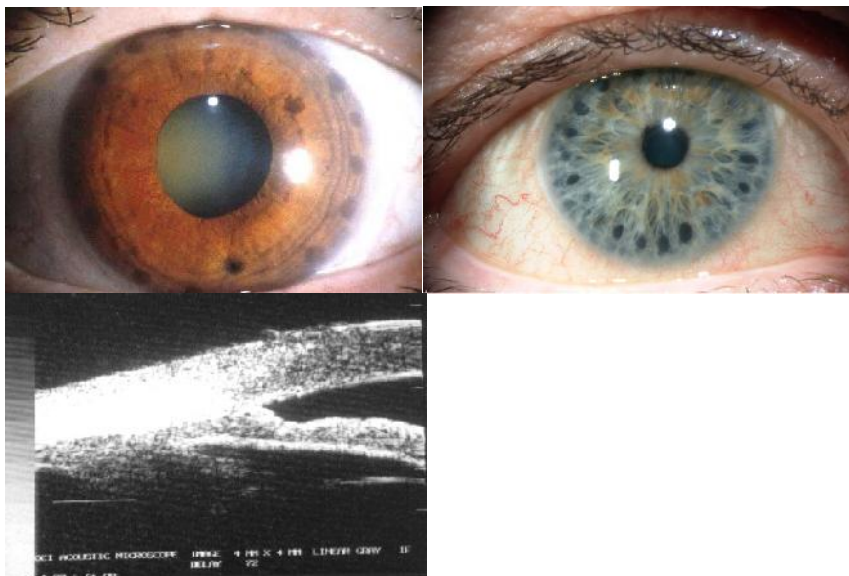
Pretreatment measures

The eye is pretreated with one drop of 4% pilocarpine or, if the patient has never had pilocarpine previously, two drops of 2% administered 5 minutes apart, to constrict the pupil, and with perioperative brimonidine to blunt a postlaser IOP spike. In AAC, moderate degrees of corneal edema are not a contraindication to ALPI. If necessary, glycerin may help clear the cornea temporarily to facilitate performing ALPI. It has also been shown that when ALPI is employed as the initial treatment in AAC, treatment to only 180° of the peripheral iris may be sufficient to abort the attack, and so obstruction to optical access to part of the peripheral iris, e.g. by pterygium, needs not be a contraindication to ALPI as initial treatment in AAC.¹⁶

Laser parameters

The argon laser is set to produce contraction burns (500 µm spot size, 0.5 to 0.7 second duration, and, initially, 240 mW power). With the Abraham iridotomy contact lens in place, the beam is aimed at the most peripheral portion of the iris possible (Figure 4). One of the most common errors resulting in failure of the procedure is spot placement in the mid-periphery of the iris rather than the extreme periphery. It is useful to allow a thin crescent of the aiming beam to overlap the sclera at the limbus. The patient may be directed to look in the direction of the beam in order to achieve more peripheral spot placement. In the lower 240 degrees of angle, the peripheral iris insertion into the angle wall can often be seen directly through the button on the lens, facilitating aiming the beam peripherally.

Figure 4. Left: Slit lamp photograph of an eye with plateau iris syndrome after ALPI. The dark, round laser marks can be clearly seen on the peripheral iris. Center: ALPI being placed too centrally, and thus ineffective. Right: UBM showing APLI being placed too centrally, and the angle remains closed.



The foot pedal or trigger should be pressed for the entire duration of the burn, unless bubble formation and pigment release occur. The contraction effect is immediate and usually accompanied by noticeable deepening of the peripheral anterior chamber at the site of the burn. The patient should be warned that he or she will feel the

burns and that a small amount of discomfort is necessary to produce adequate iris contraction. A lack of visible contraction and deepening of the peripheral anterior chamber at any site is suggestive of too low a power or PAS. The power should be increased initially to see if contraction is improved, particularly if the patient does not feel the burn. If bubble formation occurs or if pigment is released into the anterior chamber, the power should be reduced. Histopathologic examination suggests that the short-term effect is related to heat shrinkage of collagen and the long-term effect to be secondary to contraction of a fibroblastic membrane in the region of the laser application.⁵⁹ Lighter irides generally require more power than darker ones. The surgeon should adjust the power as necessary to obtain visible stromal contraction. Occasionally, in light gray irides, a 200 µm spot size may be more effective in achieving significant stromal contraction. The use of a smaller spot size requires more burns to achieve 360 degrees of contraction and, particularly with high power settings, may result in stromal destruction and pigment release.

Treatment consists of placing approximately 20-24 spots over 360°, leaving approximately 2 spot-diameters between each spot and avoiding large visible radial vessels if possible. Although rare, iris necrosis may occur if too many spots are placed too closely together. If the initial treatment is insufficient, more spots may be given at a later sitting. The presence of an arcus senilis should be ignored. An extremely shallow anterior chamber and corneal edema, which are relative contraindications to laser iridotomy, do not preclude ALPI.

Other laser settings published for this type of burn, most commonly 200 µm, 0.1 or 0.2 second duration and 200-800 mW power, often provide insufficient contraction and result in bubble formation or pigment liberation into the anterior chamber. When used through the angled mirror of a gonioscopy lens, they are more likely to result in stromal destruction or inadvertent damage to the trabecular meshwork. The laser beam strikes the iris tangentially and results in a more diffuse burn with less peripheral stromal contraction and thinning.

Two additional situations should be noted. First, when ALPI needs to be repeated because of recurrence of appositional closure at some point after the angle has been initially opened, it is possible to place the contraction burns further peripherally than had been initially possible. The reason for this is evident if one conceptualizes the geometry of the peripheral iris. When the angle is closed, burns placed just inside the point of apposition pull open the angle and expose iris stroma further peripherally. This area can be treated on a subsequent occasion if necessary.

Secondly, a few angles have a very sharply defined plateau, which on indentation forms almost a right angle and requires firm pressure to indent open. This type of plateau iris often does not completely contract with burns placed with the Abraham lens but require burns placed through one of the angled mirrors with magnification buttons of the Ritch lens or Goldmann 3-mirror lens directly into the peripheral angle. A 200 µm spot size should be used in this circumstance.

In some cases, we have performed ALPI without using pilocarpine. The technician shines a bright light, such as that from a scleral fiberoptic transilluminator, into the pupil of the fellow eye, and, with the consensual light reflex in effect in the eye to be lasered, ALPI is performed directly into the angle with the Ritch lens using 0.5 to 0.7 sec, 200 microns spot size, and, initially, 240 mW power. The advantage of this method is that the results can be immediately visualized and settings adjusted throughout the procedure to open the angle.

Apart from argon laser, the use of diode laser¹⁹ and double-frequency Nd:YAG laser^{60,61} in laser peripheral iridoplasty to treat appositional angle-closure have also been described.

Postoperative treatment

Immediately after the procedure, the patient is given a drop of topical steroid and apraclonidine or brimonidine. Gonioscopy should be performed to assess the effect of the procedure immediately if pilocarpine has not been used. If it has, it is better to evaluate the success of the procedure at a subsequent visit. Patients are treated with topical steroids four to six times daily for 3 to 5 days. Intraocular pressure is monitored postoperatively as after any other anterior segment laser procedure and patients treated as necessary if a postlaser IOP rise

Complications of ALPI and management

A mild postoperative iritis is common and responds to topical steroid treatment, seldom lasting more than a few days. The patient may experience transient ocular irritation.

Because iridoplasty is often performed on patients with extremely shallow peripheral anterior chambers, diffuse corneal endothelial burns may occur. As opposed to the dense white, sharply delineated burns seen during laser iridotomy, endothelial burns seen during ALPI are larger and much less opaque. If endothelial burns present a problem early in the procedure, they may be minimized by placing an initial contraction burn more centrally before placing the peripheral burn (kriss-kross iridoplasty). This first burn will deepen the anterior chamber peripheral to it, allowing the more peripheral burn to be placed with less adverse consequences. In virtually all cases, the endothelial burns disappear within several days and have not proven to be a major complication.¹⁵ We have seen one case of corneal decompensation following iridoplasty in a patient with preexisting Fuchs' dystrophy.

Hemorrhage does not occur because of the lower power density used to produce contraction burns as opposed to destructive ones.¹⁵ A transient rise in IOP can occur as with other anterior segment laser procedures. Lenticular opacification has not been reported.

Pigmented burn marks may develop at the sites of laser applications in some eyes treated with ALPI and are generally of no serious consequence.¹⁷ Iris atrophy may rarely develop,¹⁷ and this can be avoided by using the lowest laser power to achieve stromal contraction, and also by leaving untreated spaces between two laser application sites, and not allowing the laser marks to become confluent. When IOP is rapidly reduced in acute primary angle closure by ALPI, decompression retinopathy can rarely occur.²²

A few patients have developed dilated pupils postlaser (Urrets-Zavalía syndrome), enough to cause photophobia and/or anxiety over the appearance or to threaten a recurrence of angle-closure. Pilocarpine 2% may be administered qhs to try to bring the pupil down. This does not necessarily work in all cases, but in all cases in our experience the pupil size has normalized, although this has occasionally taken months. If the fellow eye is felt to need ALPI and the patient is willing, we will proceed. We do not know the mechanism underlying this complication, although a similar event has been reported following peripheral retinal laser treatment.⁶²

Although ALPI is highly successful long-term in eyes with plateau iris, patients need to be followed closely for recurrence of appositional closure, and if this develops, may require retreatment. Patients should be observed gonioscopically at regular intervals and further treatment given if necessary. This is most common in a patient in whom the mechanism of the glaucoma is lens-related or as the lens enlarges over time. Retreatment is only occasionally needed in patients with plateau iris,³⁸ while those with intumescent lenses usually undergo cataract extraction.

Conclusions

ALPI is a safe and simple out-patient laser procedure that effectively opens appositionally closed portions of the drainage angle. Since it does not eliminate pupillary block, laser peripheral iridotomy is still indicated if pupillary block is present.

ALPI has taken on new indications in recent years. It is now a viable alternative first-line treatment for AAC, in place of systemic IOP-lowering medications. It reduces IOP more rapidly than medications. Ongoing studies will tell whether ALPI can also reduce the rate of conversion to CACG after AAC. ALPI may also have a role in the treatment of acute phacomorphic angle-closure in the future. It is essential to keep in mind that lower power, longer duration, and larger spot sizes (contraction burns) are the most effective in achieving success with this procedure.

References

1. Ritch R. Argon laser treatment for medically unresponsive attacks of angle-closure glaucoma. *Am J Ophthalmol* 1982;94:197-204.
2. Ritch R. *Techniques of argon laser iridectomy and iridoplasty*. Palo Alto: Coherent Medical Press, 1983.
3. York K, Ritch R, Szmyd LJ. Argon laser peripheral iridoplasty: Indications, techniques and results. *Invest Ophthalmol Vis Sci* 1984;25(Suppl):94.
4. Ritch R, Solomon IS. Glaucoma surgery, 3 ed. In: L'Esperance FA, editor. *Ophthalmic lasers*. St. Louis: CV Mosby Co, 1989.
5. Ritch R. Argon laser peripheral iridoplasty: an overview. *J Glaucoma* 1992;1:206-13.
6. Ritch R, Liebmann JM, Tello C. A construct for understanding angle-closure glaucoma: the role of ultrasound biomicroscopy. *Ophthalmol Clin N Amer* 1995;8:281-293.
7. Krasnov MM. Q-switched laser iridectomy and Q-switched laser goniopuncture. *Adv Ophthalmol* 1977;34:192-6.
8. Kimbrough RL, Trempe CS, Brockhurst RJ, Simmons RJ. Angle-closure glaucoma in nanophthalmos. *Am J Ophthalmol* 1979;88:572-9.
9. Matai A, Consul S. Argon laser iridoplasty. *Indian J Ophthalmol* 1987;35:290-2.
10. Malis V. Importance of laser peripheral iridoplasty in the treatment of acute closed-angle glaucoma. *Ceska a Slovenska Oftalmologie* 2001;57:22-6.
11. Lim AS, Tan A, Chew P, et al. Laser iridoplasty in the treatment of severe acute angle closure glaucoma. *Int Ophthalmol* 1993;17:33-6.
12. Chew P, Chee C, Lim A. Laser treatment of severe acute angle-closure glaucoma in dark Asian irides: The role of iridoplasty. *Lasers and Light in Ophthalmology* 1991;4:41-2.
13. Agarwal HC, Kumar R, Kalra VK, Sood NN. Argon laser iridoplasty: A primary mode of therapy in primary angle-closure glaucoma. *Indian J Ophthalmol* 1991;39:87-90.
14. Lam DS, Lai JS, Tham CC. Immediate argon laser peripheral iridoplasty as treatment for acute attack of primary angle-closure glaucoma. A preliminary study. *Ophthalmology* 1998;105:2231-6.
15. Lam DS, Lai JS, Tham CC, et al. Argon laser peripheral iridoplasty versus conventional systemic medical therapy as the first line treatment of acute angle closure: a prospective randomized controlled trial. *Ophthalmology* 2002;109:1591-6.
16. Lai JS, Tham CC, Lam DS. Limited argon laser peripheral iridoplasty as immediate treatment for an acute attack of angle-closure glaucoma: A preliminary study. *Eye* 1999;13:26-30.
17. Lai JS, Tham CC, Chua JK, et al. Laser peripheral iridoplasty as initial treatment of acute attack of primary angle-closure: A long-term follow-up study. *J Glaucoma* 2002;11:484-7.

18. Tham CC, Lai JS, Lam DS. Immediate ALPI for acute attack of angle-closure glaucoma (addendum to previous report). *Ophthalmology* 1999;106:1042-3.
19. Lai JS, Tham CC, Chua JK, Lam DS. Immediate diode laser peripheral iridoplasty as treatment of acute attack of primary angle-closure glaucoma. A preliminary study. *J Glaucoma* 2001;10:89-94.
20. Chew PT, Wong JS, Chee CK, Tock EP. Corneal transmissibility of diode versus argon lasers and their photothermal effects on the cornea and iris. *Clin Experiment Ophthalmol* 2000;28:53-7.
21. Lam DS, Tham CC, et al. Management of acute primary angle-closure – past, present, and future. *Asia-Pacific J Ophthalmol* 2001;13:6-10.
22. Lai JS, Tham CC, Chua JK, et al. To compare argon laser peripheral iridoplasty (ALPI) against systemic medications in treatment of acute primary angle-closure: mid-term results. *Eye*. 2006 Mar;20(3):309-14.
23. Chew PT, Yeo LM. Argon laser iridoplasty in chronic angle-closure glaucoma. *Int Ophthalmol* 1995;19:67-70.
24. Rosman M, Aung T, Ang LP, et al. Chronic angle-closure with glaucomatous damage: Long-term clinical course in a North American population and comparison with an Asian population. *Ophthalmology* 2002;109:2227-31.
25. Campbell DG, Vela A. Modern goniosynechialysis for the treatment of synechial angle-closure glaucoma. *Ophthalmology* 1984;91:1052-60.
26. Kanamori A, Nakamura M, Matsui N, et al. Goniosynechialysis with lens aspiration and posterior intraocular lens implantation for glaucoma in spherophakia. *J Cataract Refract Surg* 2004;30:513-6.
27. Lai JS, Tham CC, Chua JK, Lam DS. Efficacy and safety of inferior 180° goniosynechialysis followed by diode laser peripheral iridoplasty in the treatment of chronic angle-closure glaucoma. *J Glaucoma*. 2000;9:388-91.
28. Nagata M, Nezu N. Goniosynechialysis as a new treatment for chronic angle-closure glaucoma. *Jpn J Clin Ophthalmol* 1985;39:707-10.
29. Ando H, Kitagawa K, Ogino N. Results of goniosynechialysis for synechial angle-closure glaucoma after pupillary block. *Folia Ophthalmol Jpn* 1990;41:883-6.
30. Tanihara H, Nishiwaki K, Nagata M. Surgical results and complications of goniosynechialysis. *Graefes Arch Clin Exp Ophthalmol* 1992;230:309-13.
31. Shingleton BJ, Chang MA, Bellows AR, Thomas JV. Surgical goniosynechialysis for angle-closure glaucoma. *Ophthalmology* 1990;97:551-6.
32. Teekhasaene C, Ritch R. Combined phacoemulsification and goniosynechialysis for uncontrolled chronic angle-closure glaucoma after acute angle-closure glaucoma. *Ophthalmology* 1999;106:669-75.
33. Tornquist R. Angle-closure glaucoma in an eye with a plateau type of iris. *Acta Ophthalmol* 1958;36:419-23.
34. Wand M, Pavlin CJ, Foster FS. Plateau iris syndrome: ultrasound biomicroscopic and histological study. *Ophthalmic Surg* 1993;24:129-31.
35. Ritch R. Plateau iris is caused by abnormally positioned ciliary processes. *J Glaucoma* 1992;1:23-6.
36. Pavlin CJ, Ritch R, Foster FS. Ultrasound biomicroscopy in plateau iris syndrome. *Am J Ophthalmol* 1992;113:390-5.

37. Lowe RF, Ritch R. Angle-closure glaucoma: Clinical types. In: Ritch R, Shields MB, Krupin T, editors. *The Glaucomas*. St. Louis: CV Mosby Co, 1989:839-53.
38. Ritch R, Tham CC, Lam DS. Long-term success of argon laser peripheral iridoplasty in the management of plateau iris syndrome. *Ophthalmology* 2004;111:104-8.
39. Peng D, Zhang X, Yu K. [Argon laser peripheral iridoplasty and laser iridectomy for plateau iris glaucoma]. *Chung Hua Yen Ko Tsa Chih* 1997;33:165-8. Chinese.
40. Crowston JG, Medeiros FA, Mosaed S, Weinreb RN. Argon laser iridoplasty in the treatment of plateau-like iris configuration as result of numerous ciliary body cysts. *Am J Ophthalmol*. 2005;139:381-3.
41. Weiss HS, Shingleton BJ, Goode SM, et al. Argon laser goniotomy in the treatment of angle-closure glaucoma. *Am J Ophthalmol* 1992;114:14-8.
42. Koster HR, Liebmann JM, Ritch R, Hudock S. Acute angle-closure glaucoma in a patient with acquired immunodeficiency syndrome successfully treated with argon laser peripheral iridoplasty. *Ophthalmic Surg* 1990;21:501-2.
43. Burton TC, Folk JC. Laser iris retraction for angle-closure glaucoma after retinal detachment surgery. *Ophthalmology* 1988;95:742-8.
44. Tham CC, Lai JS, Poon AS, et al. Immediate argon laser peripheral iridoplasty (ALPI) as initial treatment for acute phacomorphic angle-closure (phacomorphic glaucoma) before cataract extraction: a preliminary study. *Eye (Lond)*. 2005;19:778-83.
45. Yip PP, Leung WY, Hon CY, Ho CK. Argon laser peripheral iridoplasty in the management of phacomorphic glaucoma. *Ophthalmic Surg Lasers Imaging* 2005;36:286-91.
46. Lee JW, Lai JS, Yick DW, Yuen CY. Argon laser peripheral iridoplasty versus systemic intraocular pressure-lowering medications as immediate management for acute phacomorphic angle closure. *Clin Ophthalmol*. 2013;7:63-9. doi: 10.2147/OPHTH.S39503. Epub 2013 Jan 9.
47. Metz D, Ackerman J, Kanarek I. Laser trabeculoplasty enhancement by argon laser iridotomy and/or iridoplasty (letter). *Ophthalmic Surg* 1984;15:535.
48. Karjalainen K, Laatikainen L, Raitta C. Bilateral nonrhegmatogenous retinal detachment following neodymium-YAG laser iridotomies. *Arch Ophthalmol* 1986;104:1134.
49. Singh OS, Belcher CD, Simmons RJ. Nanophthalmic eyes and neodymium-YAG laser iridectomies. *Arch Ophthalmol* 1987;105:455-6.
50. Solomon R, Barsam A, Voldman A, et al. Argon laser iridoplasty to improve visual function following multifocal intraocular lens implantation. *J Refract Surg*. 2012;28(4):281-3. doi: 10.3928/1081597X-20120209-01. Epub 2012 Feb 15.
51. Kang JJ, Allemann N, Cortina MS, et al. Argon laser iridoplasty for optic obstruction of Boston keratoprosthesis. *Arch Ophthalmol*. 2012;130(8):1051-4.
52. Kameda T, Inoue T, Inatani M, et al. Long-term efficacy of goniosynechialysis combined with phacoemulsification for primary angle closure. *Graefes Arch Clin Exp Ophthalmol*. 2012 Jun 29. [Epub ahead of print]

53. Kanamori A, Nakamura M, Matsui N, et al. Goniosynechialysis with lens aspiration and posterior intraocular lens implantation for glaucoma in spherophakia. *J Cataract Refract.Surg*, 2004;30: 513-6.
54. Lai JS, Tham CC, Chua JK, Lam DS. Efficacy and safety of inferior 180° goniosynechialysis followed by diode laser peripheral iridoplasty in the treatment of chronic angle-closure glaucoma. *J Glaucoma* 2000;9:388-91.
55. Lai JS, Tham CC, Lam DS. The efficacy and safety of combined phacoemulsification, intraocular lens implantation, and limited goniosynechialysis, followed by diode laser peripheral iridoplasty, as the treatment of cataract and chronic angle-closure glaucoma. *J Glaucoma* 2001;10:309-15.
56. Tanihara H, Nagata M. Argon-laser goniotomy following goniosynechialysis. *Graefes Arch Clin Exp Ophthalmol* 1991, 229:505-7.
57. Prata TS, Biteli LG, Dorairaj S. Angle closure associated with a cobblestone iris configuration: clinical and imaging description. *J Glaucoma*. 2013 Dec;22(9):e36-7. doi: 10.1097/01.ijg.0000435777.99193.08.
58. Wand M. Argon laser goniotomy for synechial angle closure. *Arch Ophthalmol* 1992;110:353-7.
59. Sassani JW, Ritch R, McCormick S, et al. Histopathology of argon laser peripheral iridoplasty. *Ophthalmic Surg* 1993;24:740-5.
60. Zou J, Zhang F, Zhang L, Wang L, Huang H. A clinical study on laser peripheral iridoplasty for primary angle-closure glaucoma with positive provocative tests after iridectomy. *Zhonghua Yan Ke Za Zhi* 2002;38:708-11.
61. Zhang HC, Yao K. Peripheral iridoplasty with doubled-frequency Nd:YAG laser as treatment for angle-closure glaucoma. *Zhejiang Da Xue Xue Bao Yi Xue Ban* 2002;31:388-90.
62. Lifshitz T, Yassur Y. Accommodative weakness and mydriasis following laser treatment at the peripheral retina. *Ophthalmologica* 1988;197:65-8.